

Case Report

©2012 NRITLD, *National Research Institute of Tuberculosis and Lung Disease, Iran*

ISSN: 1735-0344 *Tanaffos* 2012; 11 (1): 63-66

TANAFFOS 

Askin's Tumor with Massive Hemoptysis

Mohammad Reza Lashkarizadeh ¹, Mitra Samareh Fekri ², Zahra Farahmandinia ³

¹ Department of Surgery, ² Department of Internal Medicine, ³ Department of Pediatrics, Afzalipour Hospital, Kerman, Iran.

Received: 28 July 2011

Accepted: 29 November 2011

Correspondence to: Lashkarizadeh MR
Address: Afzalipour Hospital, Imam Khomeini Highway, Kerman 16169391, Iran
Email address: lashkarizadeh@kmu.ac.ir

Askin's tumor is a rare neoplasm of the chest wall with a dismal prognosis and is usually observed in young subjects. We describe a 15-year-old female with massive hemoptysis who had an extensive thoracopulmonary tumor on chest CT. She underwent bronchoscopy which showed the location of the tumor in the bronchus intermedius. The biopsy obtained from the tumor enabled a diagnosis of Askin's tumor to be made. After induction of chemotherapy, hemoptysis stopped and her constitutional symptoms improved. We focus on the clinical features, imaging, and histopathological characteristics of Askin's tumor.

Key words: Askin's tumor, Chemotherapy, Ewing's sarcoma, Hemoptysis

INTRODUCTION

Primitive neuroectodermal tumors of the thoracopulmonary region are rare tumors found in children and young adults; they are referred to as "Askin's tumors" (1). Here we report a case of an Askin's tumor with massive hemoptysis. We focus on the clinical features, imaging, and histopathological aspects of this tumor.

CASE SUMMARIES

A 15-year-old female presented with hemoptysis of 5-days duration to Afzalipour Hospital (Kerman, Iran). She had three episodes of hemoptysis while hospitalized, with the final episode being massive. She had history of fever and malaise for one month before hospital admission. Her vital signs on admission were: heart rate 88 beats per minute, blood pressure 120/80 mmHg, and body temperature 37.5°C. On physical examination, crackles were heard in the right lung.

Chest radiography showed opacification in the middle of the right lung. Chest CT-scan revealed a mass in the visceral mediastinum extending to the right main and lobar bronchi (Figure 1). The patient underwent bronchoscopy which showed a tumor in bronchus intermedius, and a biopsy sample was taken.

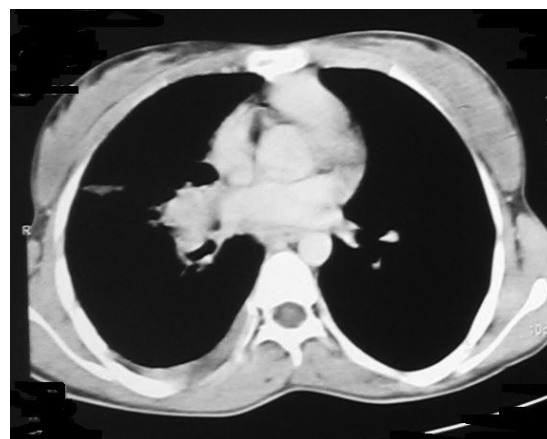


Figure 1. Chest CT-scan of the patient before chemotherapy

Biopsy samples were evaluated using histological and immunological assays. Histologically, a section from the bronchial mucosa showed a neoplastic growth comprising a nest of small-to-medium-sized cells with hyperchromatic nuclei, scant cytoplasm, and foci of necrosis (Figure 2).

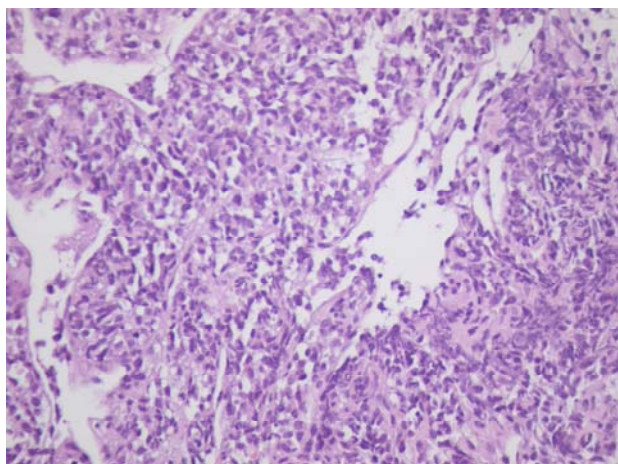


Figure 2. Hematoxylin and eosin staining (×400) of the lung biopsy specimen

Immunohistochemistry revealed that groups of cells were negative for CD99 and CD45. Tumor cells were focally positive for creatine kinase (CK) and strongly positive for neuron-specific enolase (NSE) (Figure 3).

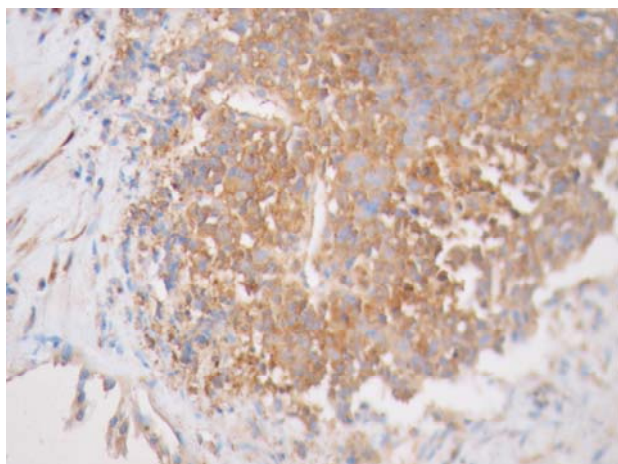


Figure 3. Immunohistochemical staining (neuron-specific enolase) of the lung biopsy specimen

Based on histopathological and immunohistochemical findings, a diagnosis of Askin's tumor was made. The tumor could not be resected due to extensive involvement

of lung tissue and the mediastinum. The patient was offered chemotherapy with alternating drug regimens (vincristine, doxorubicin, and cyclophosphamide; and isophosphamide, etoposide) for 17 cycles. She has received eight cycles of chemotherapy so far. After induction of chemotherapy, hemoptysis stopped and her constitutional symptoms improved. Chest CT at six-month follow-up showed a significant improvement (Figure 4).

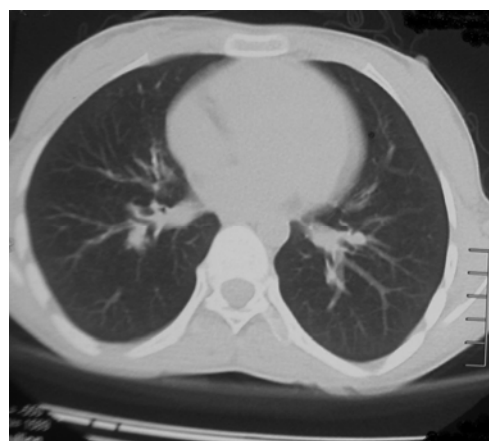


Figure 4. Chest CT of the patient after chemotherapy

DISCUSSION

Ewing's sarcoma (ES) was initially believed to be of perivascular endothelial origin. The Ewing's sarcoma family of tumors (EFT) includes ES of bone (ESB), extraosseous ES (EES), peripheral primitive neuroectodermal tumor of bone (pPNET), and malignant small-cell tumor of thoracopulmonary region (Askin's tumor). All of these tumors are now known to be neoplasms of neuroectodermal origin (2).

Askin's tumor is a rare neoplasm of the chest wall. It has a dismal prognosis and is usually observed in young subjects (3,4).

The aggressive nature of Askin's tumor results in its short clinical presentation. The diagnosis of Askin's tumor is primarily by histopathologic examination. Imaging has only a complimentary role (5).

PNET of the chest wall should be considered in a child with a chest wall mass. CT is valuable for evaluating tumor extension at diagnosis, the effects of chemotherapy, and

assessing tumor recurrence after surgery. However, CT can overestimate infiltration into the pleura, lung or diaphragm, and it would be better evaluated by ultrasonography. MRI is superior to CT for evaluation of tumor extension, and may be considered complementary to CT, particularly for very large tumors of the chest wall (6).

Kabiri and colleagues emphasized on the difficult histological diagnosis, and demonstrated the importance of complete removal of the tumor for survival (7).

Takanami and colleagues reported a case of a 16-year-old male who underwent surgery for excision of Askin's tumor. He subsequently underwent six excisions of local Askin's tumors due to recurrence, with postoperative chemotherapy and radiotherapy for a 7-year period (8).

The established treatment of this tumor is neo-adjuvant chemotherapy followed by surgical excision of the tumor and post operative chemotherapy with or without radiotherapy (9,10). The neo-adjuvant chemotherapy results in better regional management of the tumor, less extensive surgery and can treat the distant metastasis. The studies on Ewing's sarcoma patients demonstrated that deferred surgical excision of tumor subsequent to chemotherapy leads to a more negative margin as compared to cases who underwent surgery alone (9). Chemotherapy in the past consisted of a combination of Vincristine, Actinomycin-D, and Cyclophosphamide. Currently, Doxorubicin is added to the regimen in the majority of protocols. Additional drugs administered in most patients are Ifosfamide and Etoposide (11). Operation with wide margins is ideal, but occasionally is feasible in patients with chest wall tumors. Patients with positive margin of tumor after surgery need post operative radiation. Due to the delayed complications of radiotherapy such as pulmonary impairment and amplified cardiac toxicity with the prescription of anthracyclines, adequate treatment should be planned ahead to avoid such complications (10, 12).

The age of presented case was older than most patients with Askin's tumor.

Older age (>14 years) has constantly been correlated with a poorer survival rate from EWS (13). The reason for this is unclear, as recent surveys showed no difference in metastasis at diagnosis, or histological response to neo-adjuvant therapy. Patients treated at referral centers showed to have better outcomes. Superior survival rate among children compared to adults may be related to higher familiarity of pediatric oncologists with this disease and its available treatment options (14).

In our literature review, most articles about Askin's tumor were case reports. These cases mainly presented as a mass in the chest wall with or without pulmonary involvement, and the diagnosis was made by biopsy from the mass. In our case, we could diagnose Askin's tumor by a minor procedure. The patient had advanced disease and the tumor could not be resected. She; therefore, underwent chemotherapy and a significant response was observed.

In conclusion, if Askin's tumor manifests with massive hemoptysis, the diagnosis can be reached with bronchoscopy. If the tumor is extensive, chemotherapy can be used to stop hemoptysis.

REFERENCES

1. Takanami I, Imamura T. The treatment of Askin tumor: results of two cases. *J Thorac Cardiovasc Surg* 2002; 123 (2): 391- 2.
2. Carvajal R, Meyers P. Ewing's sarcoma and primitive neuroectodermal family of tumors. *Hematol Oncol Clin North Am* 2005; 19 (3): 501- 25, vi-vii.
3. Katsenos S, Nikopoloulou M, Kokkonouzis I, Archondakis S. Askin's tumor: a rare chest wall neoplasm. Case report and short review. *Thorac Cardiovasc Surg* 2008; 56 (5): 308- 10.
4. Ayadi H, Ayoub AK. Askin tumor: two cases. *Rev Pneumol Clin* 2002; 58 (6 Pt 1): 347- 50.
5. Aggarwal M, Lakhhar B, Aggarwal BK, Anugu R. Askin tumor: a malignant small cell tumor. *Indian J Pediatr* 2000; 67 (11): 853- 5.
6. Sallustio G, Pirroni T, Lasorella A, Natale L, Bray A, Marano P. Diagnostic imaging of primitive neuroectodermal tumour of the chest wall (Askin tumour). *Pediatr Radiol* 1998; 28 (9): 697- 702.

7. Kabiri H, el Fakir Y, Mahassini N, Benamor J, Alaziz S, Elmaslout A, et al. Malignant small-cell thoracic pulmonary tumor (Askin tumor). *Rev Pneumol Clin* 1999; 55 (1): 21- 5.
8. Takanami I, Imamura T, Naruke M, Kodaira S. Long-term survival after repeated resections of Askin tumor recurrences. *Eur J Cardiothorac Surg* 1998; 13 (3): 313- 5.
9. Christiansen S, Semik M, Dockhorn-Dworniczak B, Rötger J, Thomas M, Schmidt C, et al. Diagnosis, treatment and outcome of patients with Askin-tumors. *Thorac Cardiovasc Surg* 2000; 48 (5): 311- 5.
10. Parikh M, Samujh R, Kanojia RP, Mishra AK, Sodhi KS, Bal A. Peripheral primitive neuroectodermal tumor of the chest wall in childhood: clinico-pathological significance, management and literature review. *Chang Gung Med J* 2011; 34 (2): 213- 7.
11. van den Berg H, van Rijn RR, Merks JH. Management of tumors of the chest wall in childhood: a review. *J Pediatr Hematol Oncol* 2008; 30 (3): 214- 21.
12. Shamberger RC, Laquaglia MP, Krailo MD, Miser JS, Pritchard DJ, Gebhardt MC, et al. Ewing sarcoma of the rib: results of an intergroup study with analysis of outcome by timing of resection. *J Thorac Cardiovasc Surg* 2000; 119 (6): 1154- 61.
13. Cotterill SJ, Ahrens S, Paulussen M, Jürgens HF, Voûte PA, Gadner H, et al. Prognostic factors in Ewing's tumor of bone: analysis of 975 patients from the European Intergroup Cooperative Ewing's Sarcoma Study Group. *J Clin Oncol* 2000; 18 (17): 3108- 14.
14. Subbiah V, Anderson P, Lazar AJ, Burdett E, Raymond K, Ludwig JA. Ewing's sarcoma: standard and experimental treatment options. *Curr Treat Options Oncol* 2009; 10 (1-2): 126- 40.